Rupture of a Giant Mesenteric Cyst after a Penetrating Abdominal Trauma

Fatih Yanar, Orhan Agcaoglu, Beyza Ozcinar, Ozgur Mete[1], Kayihan Gunay
From the Departments of General Surgery and Pathology[1], Istanbul University, Istanbul School of Medicine, Istanbul, Turkey.

Abstract:

Benign cystic tumors are rare intra-abdominal lesions that may be retroperitoneal, mesenteric, or omental. Their rarity had fostered a lack of information and difficulty in classification. Most of them cause non-specific symptoms, rarely they cause serious complications such as volvulus, rupture or bowel obstruction and treatment is indicated if they become symptomatic due to enlargement of the cyst. We present a patient with a ruptured giant mesenteric cyst due to a penetrating abdominal trauma and treated successfully by surgical intervention. To our best of knowledge, this is the first case reported in the English literature with a ruptured mesenteric cyst after penetrating abdominal trauma.

Key words: Cysts, Intestinal Obstruction, Intestinal Volvulus, Mesenteric Cysts, Wounds, Stab.

Introduction

Mesenteric cysts are rare intra-abdominal findings and since the first reported case in 1507 by the Florentine anatomist Benevieni [1], approximately 800 cases have been reported in the literature [2-4]. The incidence varies from 1 per 1,00,000 to 2,50,000 [2,4,5] admissions in the adult population and 1:20,000 in children, with a male:female ratio of 1:1 [1,6]. Although about one-third of the patients involved are under 10 years of age, most of the cases occur in the third decade of life [1,6].

The etiopathogenesis of the disease is unknown, although it is thought that dysembryogenetic factors, abdominal trauma, lymphatic obstruction or a local degeneration of some lymph nodes may possibly lead to the formation of such cysts [7]. There are reported cases of rupture of a mesenteric cyst due to a blunt trauma [8,9], but to best of our knowledge this is the first case in literature reported as a mesenteric cyst ruptured due to a penetrating trauma.

Case Report

A 43 year old man was admitted to with history of stabbing and head trauma. He was beaten and also stabbed just 40 minutes before admission. He was conscious and co-operative, a little amazed, with a mild abdominal pain. He was hemodynamically stable (BP: 130/90 mmHg, HR: 88/min). Both lungs

Corresponding Author: Dr. Fatih Yanar
Email: yanar_fatih@yahoo.com
Received: January 13, 2014 | **Accepted:** February 12, 2014 | **Published Online:** March 15, 2014

Conflict of interest: None declared | **Source of funding:** Nil | **DOI:** http://dx.doi.org/10.17659/01.2014.0024

were well aerated and the heart sounds were normal. He had a haematoma on inferior lip and a periorbital haematoma, one stab wound at the right upper quadrant of the abdomen 4 cm lateral to the umbilicus, 3 cm below the arcus costarum on the midclavicular line in 3 cm length, and an other 4 cm stab wound at the anterolateral side of the right femur. Abdominal examination revealed only a localized tenderness at the right upper quadrant. The bowel sounds were normoactive. Rectal examination showed stool without blood. There was no significant axillary-rectal temperature difference. The nasogastric tube content was bile-stained. The femoral, popliteal and dorsalis pedis arteries were palpable at the stabbed leg and there was no ankle-brachial index difference between the two legs. Abdominal wound exploration revealed posterior fascial penetration and the fascial defect was closed after the debridment of the wound. Cefazolin was administered intravenously and the patient recieved tetanus toxoid. The blood count was in normal ranges on admission (WBC: 10600/mm^3, Hematocrit: 39%). The posteroanterior chest X-ray and abdominal X-ray was normal. After 30 minutes of admission, abdominal ultrasound examination was reported as normal. Cranial computed tomography scan performed because of the head trauma was found to be normal. Patient was taken to the selective management protocol by periodical abdominal physical examination and blood counts for detecting leukocytosis and hematocrit levels. The enteral feeding was stopped, adequate intravenous hydration was obtained. The white blood cell count elevated to 17200/mm^3 and 18100/mm^3 on the fourth and eighth hours of admission, respectively. Also hematocrit levels decreased to 35% and 30% within the same time periods after admission. The patient was more painful, was presented a generalized abdominal tenderness and significant rebound-tenderness after 8 hours.

Laparoscopy was performed under general anaesthesia. The initial 10 mm trocar was placed in the infraumblical region using the open Hasson technique, and the abdomen was explored via a 30^0 laparoscopic camera. The intra-abdominal appearance we encountered was so unusual, and extra-ordinary. The diagnostic laparoscopy revealed an injury at a hollow viscus resembling the stomach but could not distinguish the exact organ affected, there was bile-stained and also sero-haemorrhagic fluid in the abdomen. We were not able to visualize the small intestines despite the normal appearance of the colon, spleen, and the liver and decided to convert to an open surgical exploration.

Laparotomy revealed a cystic mass 20x20x15 cm in size, nearly occupying the left hemi-abdomen and expanding to right side, without well-defined borderlines. We aspirated approximately 2 litres of serohaemorrhagic and bile-stained fluid from the abdominal cavity. There was a 2 cm stab wound on the right upper wall of the cyst. The outer surface was smooth, grayish-white in color. Cystotomy was performed for further examination. There was a serohaemorrhagic intracystic fluid. There were no intra-cystic septations. On detailed examination we saw that the cyst originated from the ligament of Treitz, with involvement of whole transverse, left and sigmoid mesocolons. The cyst was expanding to the retroperitoneum at the posterior side of the cecal mesocolon. After the total cyst resection, the small intestine segment between 100 to 130 cm away from the ligament of Treitz was resected in view of stab wounds and mesenteric injury. A double-layered end to end anastomosis was performed.

The postoperative course was uneventfull and the patient was discharged on the sixth day of the operation. Background history of the patient exhibited intermittent abdominal pain and discomfort since the childhood when enquired retrospectively. The histopathological examination revealed a mesenteric cyst. The surface epithelium was not

present due to the presence of extensive erosion. In some areas, the presence of a cuboidal lining epithelium was observed. A chronic inflammatory reaction admixed with acute inflammation was also present in the wall of this giant cyst [Fig.1,2].

Discussion

De Perrot and co-workers [10] reported a new classification in 2000, based essentially on histopathological features including the following groups: (i) cysts of lymphatic origin (simple lymphatic cyst and lymphangioma); (ii) cysts of mesothelial origin (simple mesothelial cyst, benign and malignant cystic mesothelioma); (iii) cysts of enteric origin (enteric cyst and enteric duplication cyst); (iv) cysts of urogenital origin; (v) mature cystic teratoma (dermoid cyst); and (vi) pseudocysts (infectious and traumatic cysts).

Mesenteric cysts can be located anywhere in the mesentery, from the duodenum to the rectum [1,2,4]. The most frequent site is the small bowell mesentery (60%), followed by the mesocolon (24%), and the retroperitoneum (14.5%), while it is indefinite in 1.5% of cases [10]. It is located especially in the ileum when seen in the small bowell [5,11]. To define the origin in our case was challenging and excepted in the 1.5% group of the cases reported.

There are no pathognomonic signs or symptoms for the diagnosis of mesenteric cystic formations [1,2,5,6]. The presenting symptoms depend on the size and location, and the cysts may be presented in one of these 3 ways: (i) non-specific abdominal features; (ii) an incidental finding or (iii) an acute abdomen [5]. The first clinical sign is pain or abdominal distention often occuring intermittently and non-specifically for some time, as our patient experienced previously (we learned when we retrospectively asked). Abdominal mass is found in more than 50% of cases and 40% of cases are discovered incidentally [5]. Constipation, abdominal discomfort and anorexia have been reported as a nonspecific symptoms [2]. Few mesenteric cysts may be presented as an acute abdomen due to a complication such as hemorrhage, rupture or torsion of the cyst [12].

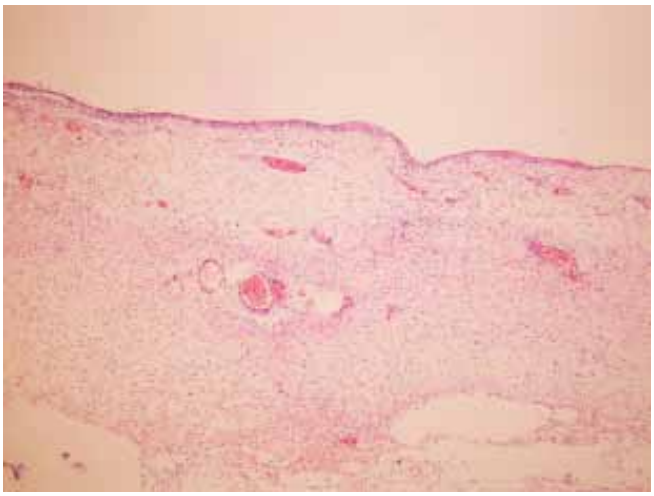

Fig.1: Cuboidal epithelium at the surface and inflammatory reaction in the wall (H&E, original magnification).

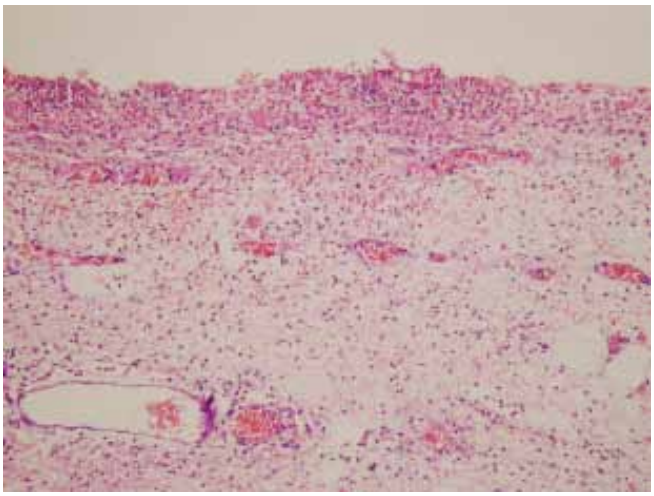

Fig.2: Erosion at the surface epithelium, inflammation and dilated blood vessels (H&E, original magnification).

The most common physical finding of a retroperitoneal or mesenteric cyst is a compressible abdominal mass, movable transversely but not longitudinally; omental cysts are freely movable [11]. The acute trumatic clinical presentation of our case made it impossible to deeply palpate the abdomen so we could not have a preoperative suspicion of a mesenteric cyst. Diagnostic aids include abdominal computed tomography, magnetic resonance imaging, ultrasound scan [2,3,11]. Mesenteric cysts exhibits so many patterns on ultrasound, but an oval mesenteric mass encountered must be considered as a possible mesenteric cyst [13]. Also preoperative radiologic work-up is needed to demonstrate the nature of these lesions and to distinguish them from malignant masses [2,6] in elective cases. Unfortunately, we could not recieve any information from preoperatively performed ultrasonography. It is hard to understand such a giant mass omitted ultrasonographically. Computed tomography was not performed according to our protocols on penetrating abdominal trauma.

Treatment is indicated if they become symptomatic due to enlargement of the cyst [3] . Complete excision is the treatment of choice because of the possibilities of recurrence and malignant transformation seen in 3% of cases [1-7] . The laparoscopic approach is replacing open surgical procedures [2,4,14,15]. Partial bowel resection may be necessary because of the transecting neighboring bowel vessels [7,11]. All the treatment recommendations, especially about laparoscopy are made for elective cases and for more smaller cysts in the literature available. The operation was started laparoscopically, but converted to laparatomy cause of the challanges mentioned above. But we think that smaller sized cysts even in the emergency situations may be resected successfully in selected patients by laparoscopic procedures.

This case is worth presenting because of the unusual presentation and also for discussing the entities that should be remembered in the differential diagnosis.

References

1. Kurtz RJ, Heimann TM, Beck AR, Holt J. Mesenteric and retroperitoneal cysts. Ann Surg. 1986;203:109-112.
2. Asoglu O, Igci A, Karanlık H, Parlak M, Kecer M, Ozmen V, *et al*. Laparoscopic treatment of mesenteric cysts. Surgical Endoscopy. 2003;17:832.
3. Shamiyeh A, Rieger R, Schrenk P, Wayand W. Role of laparoscopic surgery in treatment of mesenteric cysts. Surg Endos. 1999;13:937-939.
4. Dequanter D, Lefebvre JC, Belva P, Takieddine M, Vaneukem P. A case treated by laparoscopy and a review of the literature. Surgical Endoscopy. 2002;16:1493.
5. Liew SC, Glenn DC, Storey DW. Mesenteric cyst. Aust N Z J Surg. 1994;64: 741-744.
6. Saviano MS, Fundaro S, *et al*. Mesenteric cystic neoformations: report of two cases Surg Today. 1999;29:174-177.
7. Hardin HJ, Hardy JD. Mesenteric cysts . Am J Surg. 1970;119:640-645.
8. Vlazakis SS, Gardikis S, Sanidas E, Vlachakis I, Charissis G. Rupture of mesenteric cyst after blunt abdominal trauma. Eur J Surg. 2000;166:262-264.
9. Ulman I, Herek O, Ozok G, Avanoglu A, Erdener A. Traumatic rupture of mesenteric cyst : a life threatening complication of a rare lesion. Eur J Pediatr Surg. 1995;5:238-239.
10. de Perrot M, Brundler M, Totsch M, Mentha G. Mesenteric cysts. Toward less confusion? Dig Surg. 2000;17:323-328.
11. Vanek VW, Philips AK. Retroperitoneal, mesenteric, and omental cysts. Arch Surg. 1984;119:838-842.
12. Takkal M, Ionescu G, Becker JH *et al*. A complication of mesenteric lymphangioma: case report and brief review of literature. Acta Chir

Belg. 1996;96:130-132.
13. Sato M, Ishida H, Konno K, Komatsuda T, Konno S, Watanabe S, *et al*. Mesenteric cyst : Sonographic findings. Abdom Imaging. 2000;25:306-310.
14. Mihmanli I, Erdogan N, Kurugoglu S, Aksoy SH, Korman U. Radiological workup in mesenteric cysts : insight of a case report. Clin Imaging. 2001;25:47-49.
15. Polat C, Ozacmak ID, Yucel T, Ozman Y. Laparoscopic resection of giant mesenteric cyst. J Laparoendosc Adv Surg Tech. 2000;10:337-339.