Xanthogranulomatous Oophoritis Mimicking as an Ovarian Neoplasm

Suryawanshi Kishor H, Damle Rajshri P, Dravid NV
From the Department of Pathology, JMF's ACPM Medical College, Dhule, India.

Abstract:

Xanthograulomatous inflammation of genital tract is rare with only few cases of xanthograulomatous oophoritis reported from India in the literature. Ovarian mass lesion formation leads to clinical and radiological misdiagnosis of ovarian neoplasm in most of the cases. Hence, though rare, in female genital tract, knowledge and consideration of this distinct inflammatory lesion should be there while treating patient with tubo-ovarian mass to avoid unnecessary radical surgical procedures especially in young females. Herein, we report a case of xanthograulomatous oophoritis in a 32 year female mimicking an ovarian neoplasm.

Key words: Ovarian Neoplasms, Oophoritis, Ovary, Inflammation.

Introduction

Xanthograulomatous inflammation is a distinct uncommon type of chronic inflammation that leads to destruction of tissue of the affected organ. Microscopically it is characterised by destruction and replacement of tissue by a large number of lipid containing macrophages with an admixture of lymphocytes, plasma cells, multinucleated giant cells and neutrophils [1]. Xanthograulomatous inflammation of female genital tract is uncommon and limited to endometrium. Only a few cases involving the ovary have been reported [2]. Its presentation as mass lesion in pelvic cavity and invasion of surrounding tissue can lead to misdiagnosis of neoplastic lesion. Also radiological and gross features of xanthograulomatous oophoritis mimics ovarian neoplasm [3].

Herein, we report a case of xanthograulomatous oophoritis in a 32 year female who was clinically and radiologically misdiagnosed as ovarian neoplasm and discuss the review of literature. Histopathological findings revealed characteristics features of xanthograulomatous oophoritis.

Case Report

A 32 year female presented to gynaecology OPD with complaints of lower abdominal pain, white discharge per vagina since 5-6 months and fever intermittently since 15 days. She had one child and her past menstrual history was unremarkable. Physical examination revealed tenderness on deep palpation in left lower abdomen. Gynaecological examination revealed cervical erosion with tenderness and vague defined mass measuring approximately 6x4x3.5 cm in left adnexal region.

Corresponding Author: Dr. Suryawanshi Kishor H.
Email: ompathologylab@gmail.com
Received: February 14, 2014 | **Accepted:** March 11, 2014 | **Published Online:** March 20, 2014

Conflict of interest: None declared | **Source of funding:** Nil | **DOI:** http://dx.doi.org/10.17659/01.2014.0025

Routine haematological examination investigations showed microcytic hypochromic anaemia with neutrophilic leucocytosis and ESR of 40 mm/hr. Renal function test, liver function test, urine routine examination were within normal limits. Urine pregnancy test was negative. Pap smear examination revealed non-specific cervicitis. Test for tumor markers including CEA, CA125 and AFP were within normal limits. Pelvic ultrasonography showed normal size uterus with left ovarian mass measuring 7x4.5x4 cm with predominant solid areas with cystic change. Right ovary was normal. Based on these findings clinical diagnosis of ovarian neoplasm was made.

During exploratory laparotomy left ovarian mass was found with no ascites or omental deposits. Right ovary was normal. Left salpino-oophorectomy was done and specimen was sent for histopathological examination. Grossly, specimen measured 8x6x5 cm. Ovary was replaced by solid,yellow, lobulated mass. Cut section showed foci of yellowish white area [Fig.1]. Microscopic examination showed diffuse and dense infiltration of ovarian tissue by sheets of foamy histiocytes, lymphocytes, plasma cells and polymorphs. Areas of abscess formation and fibrosis separated by hyalinised stroma were noted [Fig.2-3]. Z.N. stain of section was negative for acid fast bacilli. Based on characteristics histomorphological features diagnosis of xanthograulomatous oophoritis was made. Patient was discharged on 7th postoperative day with uneventful recovery.

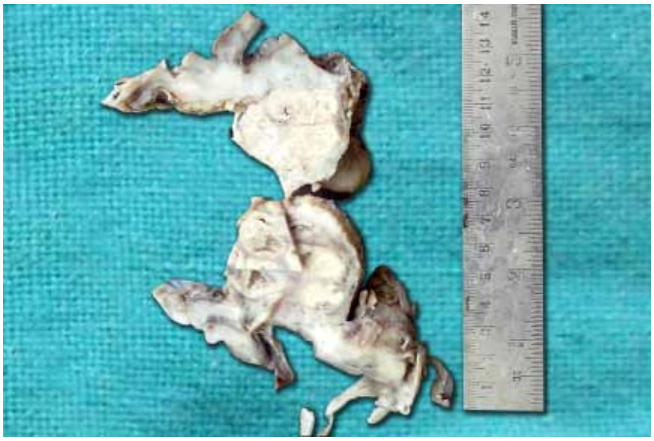

Fig.1: Ovary is replaced by solid, yellow, lobulated mass. Cut section showed foci of yellowish white area.

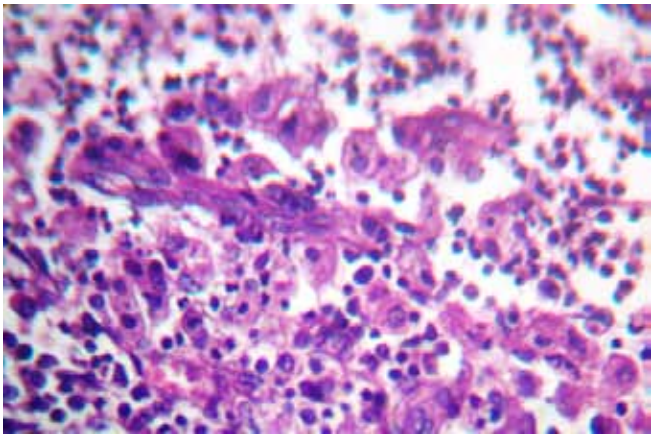

Fig.2: Microscopic examination showed diffuse and dense infiltration of ovarian tissue by sheets of foamy histiocytes, lymphocytes, plasma cells and polymorphs.

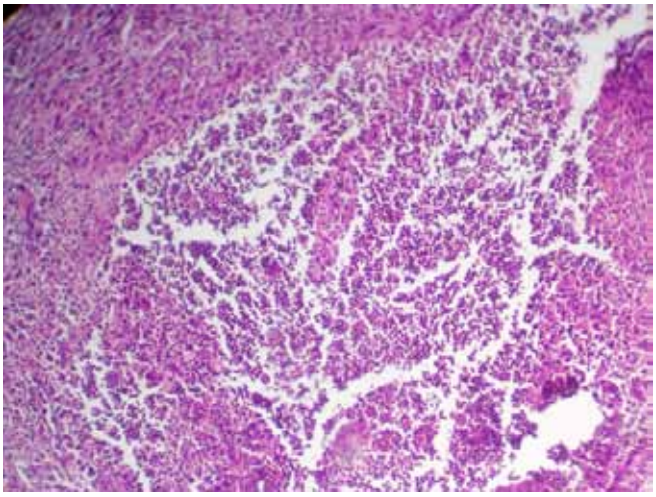

Fig.3: Areas of abscess formation and fibrosis separated by hyalinised stroma were noted.

Discussion

Xanthograulomatous inflammation of the female genital tract is very rare and confined to the endometrium; however involvement of vagina, cervix, fallopian tube and ovary has been documented. Only a few cases of xanthograulomatous oophoritis have been reported from India [2]. It is a special form of chronic inflammation that is destructive to normal tissue of affected organs. The most common organs affected are kidney and gall bladder [4]. Other organs affected by this type of inflammation are stomach, anorectal area, bone, urinary bladder, testis, epididymis [5-10]. Xanthograulomatous inflammation occurring in female genital tracts affects endometrium, fallopian tubes or ovaries focally or entirely; which clinically forms mass lesion in the pelvic cavity and may invade the surrounding tissues [11].

Only 15 related cases of xanthograulomatous oophoritis of fallopian tube or ovary have been reported in the literature [11]. Grossly, the involved ovary is enlarged and replaced by a solid, yellow lobulated well circumscribed mass, sometimes involving adjacent organs, thereby mimicking malignancy [2]. Average age of patients with affected ovary is 31 years. Microscopically, the affected organs suffer disorganisation and infiltration of sheets of foamy cells admixed with mixture of inflammatory cells such as lymphocytes, plasma cells, neutrophils with or without multinucleated giant cells [12].

The etiopathogenesis of xanthograulomatous oophoritis remains unclear. Many theories have been proposed such as theory of infection, IUCD, endometritis, inborn lipid metabolism of macrophages and drugs. The most accepted theory is of infection which is supported by clinical evidence of infection and growth of bacteria such as *E.Coli, Bacteroides fragilis, Proteus* and *Salmonella typhi* from the affected tissue by culture [11,13].

Differential diagnosis of xanthograulomatous oophoritis includes infections like tuberculosis, fungal infections which can be ruled out by culture and special stains for the causative organisms. Malakoplakia which commonly occurs in the urinary system is one of the confusing differential diagnosis of xanthograulomatous inflammation. In malakoplakia, the cytoplasmic concentric calcific bodies (Michaelis-Gutmann bodies) are found which were absent in the present case ruling out this condition. Immunohistochemistry helps in confirming the diagnosis including CD68 (foam cell positive), CD3 (T lymphocyte marker), CD20 (B lymphoma marker). But it is seldom required in presence of characteristics histomorphological features.

Treatment of choice for xanthograulomatous oophoritis is oophorectomy. The clinical manifestations, imaging modalities and gross features of xanthogranulomatous oophoritis mimics ovarian malignancy leading to radical surgical treatment especially in young patients; a preoperative diagnosis of this entity should be considered to avoid radical surgical treatment. Patient with PID, endometritis, IUCD users should be followed up because of their close association with this entity.

References

1. Sun Ho Kim, Seung Hyup Kim, Dal Mo Yang, Kyeong A Kim. Unusual causes of tubo-ovarian abscess: CT and MRI Imaging Findings. Radiogrphics. 2004;24(6):1575-1589.
2. Shukla S, Pujani M, Singh SK, Pujani M. Xanthogranulomatous oophoritis associated with primary infertility and endometriosis. Indian J Pathol Microbiol. 2010;53:197-198.
3. Mahesh Kumar U, Potekar RM, Yelikar BR, Pankaj Pande. Xanthogranulomatous oophoritis-masquerading as ovarian neoplasm. Asian J

Pharm and Sci. 2012;2(2):308-309.
4. Mittal BV, Badhe BP. Xanthogranulomatous pyelonephritis (a clinico-pathological study of 15 cases): Journal of Postgraduate Medicine. 1989;35(4):209-214.
5. Guarino M, Reale D, Micoli G, Tricomi P, Cristofori E. Xanthogranulomatous gastritis: association with xanthogranulomatous cholecystitis. J Clin Pathol. 1993;46:88-90.
6. Cozzutto C. Xanthogranulomatous osteomyelitis Arch Pathol Lab Med. 1984;108:973-976.
7. Usamentiaga E, Val-Bernal JF, Alonso-Bartolome´ P, Lo´pez-Rasines G, del Valle JI, Calabia A. Xanthogranulomatous orchitis. Urology. 1998;52:891-892.
8. Wiener LB, Riehl PA, Baum N. Xanthogranulomatous epididymitis: a case report. J Urol. 1987;138:621–622.
9. Russack V, Lammers RJ. Xanthogranulomatous endometritis: report of six cases and a proposedmechanism of development. Arch Pathol Lab Med. 1990;114:929-932.
10. Pace EH, Voet RL, Melancon JT. Xanthogranulomatous oophoritis: an inflammatory pseudo-tumor of the ovary. Int J Gynecol Pathol. 1984;3:398-402.
11. Xiang-sheng Zhang, Hong-yan Dong, Lei-lei Zhang, Mohamed Mokhtar Desouki, Chengquan Zhao. Xanthogranulomatous Inflammation of the Female Genital Tract: Report of Three Cases. Journal of Cancer. 2012;3:100-106.
12. Kalloli M, Bafna UD, Mukherjee G, Devi UK, Gurubasavangouda, Rathod PS. A Rare Xanthogranulomatous Oophoritis Presenting as Ovarian Cancer. Online J Health Allied Scs. 2012;11(2):11.
13. Gray Y, Libbey NP. Xanthogranulomatous salpingitis and oophoritis: A case report and review of the literature. Arch Pathol Lab Med. 2001;125:260-263.