doi:10.17659/01.2025.0018

Journal of Case Reports 2025;15(3):66-69

Amphicrine Carcinoma of the Small Bowel: A Pathological Conundrum

Himangsu Sarma[1], Hariharan Ramesh[1], Agam Sharma[1], Ami M Emmanuel[2]

Departments of [1]Surgical Gastroenterology and [2]Pathology, Lakeshore Hospital and Research Centre, Kochi, Ernakulam, Kerala - 682040, India.

Corresponding Author:
Dr Himangsu Sarma
Email: himangsu59@gmail.com

This is an Open Access article distributed under the terms of the Creative Commons Attribution License (creativecommons.org/licenses/by/3.0).

Received : November 17, 2024
Accepted : April 7, 2025
Published : September 5, 2025

Abstract

Background: Amphicrine tumors of small bowel are rare lesions of the gastrointestinal tract that exhibit both neuroendocrine and exocrine features. It is an uncommon lesion with distinct biological and histological features. No clear guidelines on management of amphicrine carcinomas have been documented so far. *Case Report*: Here we report the case of a 60-year-old female who presented with abdominal pain and weight loss. Initial imaging suggested terminal ileitis favouring Crohn's disease or tuberculosis. She underwent a limited ileo-caecal resection and the postoperative histopathological examination unexpectedly revealed neoplastic cells with both neuroendocrine and exocrine components, consistent with amphicrine carcinoma. Postoperatively, she is on regular follow-up without any recurrence. *Conclusion*: This report aims to help physicians understand the disease better, and to differentiate it from other mixed tumors in order to reduce the rate of clinical and pathological misdiagnosis.

Keywords: Abdominal Pain, Carcinoma, Histopathology, Ileum, Neuroendocrine Tumors, Weight Loss.

Introduction

Amphicrine tumors, in which endocrine and epithelial cell constituents are present within the same cell, are very rare. To date, cases of amphicrine carcinoma have been documented in the pancreas, stomach, rectum, breast, thyroid, and genitourinary tract [1,2]. It is strikingly different from mixed adeno-neuroendocrine carcinoma (MANEC) where each component accounts for approximately 30% of the tumor [2]. This case is reported due to the extreme rarity of amphicrine carcinoma in the small bowel, which often mimics more common inflammatory or malignant conditions, leading to diagnostic challenges. Documenting its clinical course and pathological features will aid in better recognition and management of this uncommon entity.

Case Report

A 60-year-old female presented with a two-month history of abdominal pain, intermittent vomiting and weight loss (6 kg) in 2023. She was evaluated and found to have terminal ileitis on ultrasound. Endoscopy showed features of peptic ulcer disease. Contrast-Enhanced Computed Tomography (CECT) showed multiple concentric long segment circumferential wall thickenings in distal ileum with stricture along with mesenteric lymphadenopathy suggesting either Crohn's disease, tuberculosis or malignancy **[Fig.1]**. She came to our hospital for further evaluation. Routine investigations were normal. CEA and CRP were normal. Mantoux test was negative. A colonoscopy showed terminal ileitis, colitis and proctitis. Biopsy suggested only inflammation. Repeat CECT suggested similar findings. In view of persistent symptoms, she underwent diagnostic laparoscopy with limited ileocecal resection in August 2023. She was then discharged on the seventh postoperative day.

Gross specimen showed thick, narrow and ulcerated ileal segment measuring 6.5×2.5×1 cm

and extending up to the ileocecal valve **[Fig.2a,b]**. Neoplastic cells were arranged as tubules, nests and trabeculae resembling intestinal crypts. Other areas show signet ring/goblet like mucinous cells. Four out of eighteen lymph nodes showed metastatic carcinoma. The neoplastic cells also exhibited diffuse positivity for CEA, CDX2, Synaptophysin, Chromogranin and p53 **[Fig.3a,d]**. PAS stain was positive highlighting the extracellular mucin. Altogether, this suggested amphicrine carcinoma of ileum with lympho-vascular and perineural invasion (pT4N2 disease). She received eight cycles of adjuvant capecitabine-oxaliplatin chemotherapy. One year follow-up showed disease recurrence at previous anastomotic site **[Fig.1d]**. She is currently under strict medical oncology follow-up.

Discussion

Amphicrine neoplasms are tumors with exocrine and neuroendocrine components in the same cell. Feyrter in 1938 first suggested the coexistence of endocrine and exocrine secretory products within single cells which was later coined by Ratzenhofer as "amphicrine" carcinoma. World Health

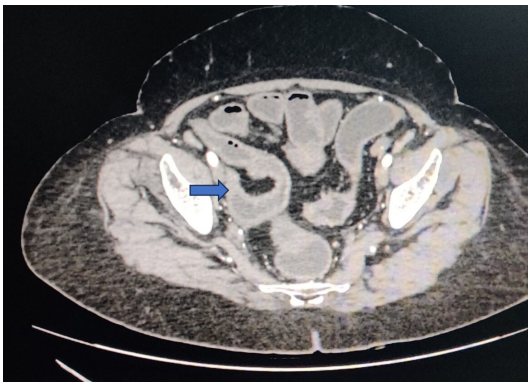

Fig.1: *Contrast enhanced computed tomography shows multiple concentric long segment circumferential wall thickening in distal ileum (arrow).*

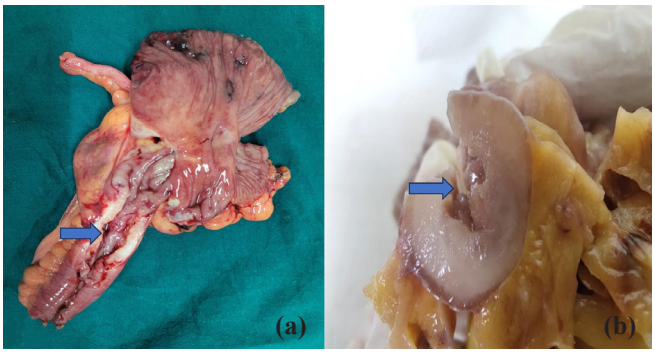

Fig.2 (a,b): *Gross specimen shows ileal segment measuring 6.5×2.5×1 cm which is thickened, narrowed with an ulceration extending upto the ileocecal valve (arrows).*

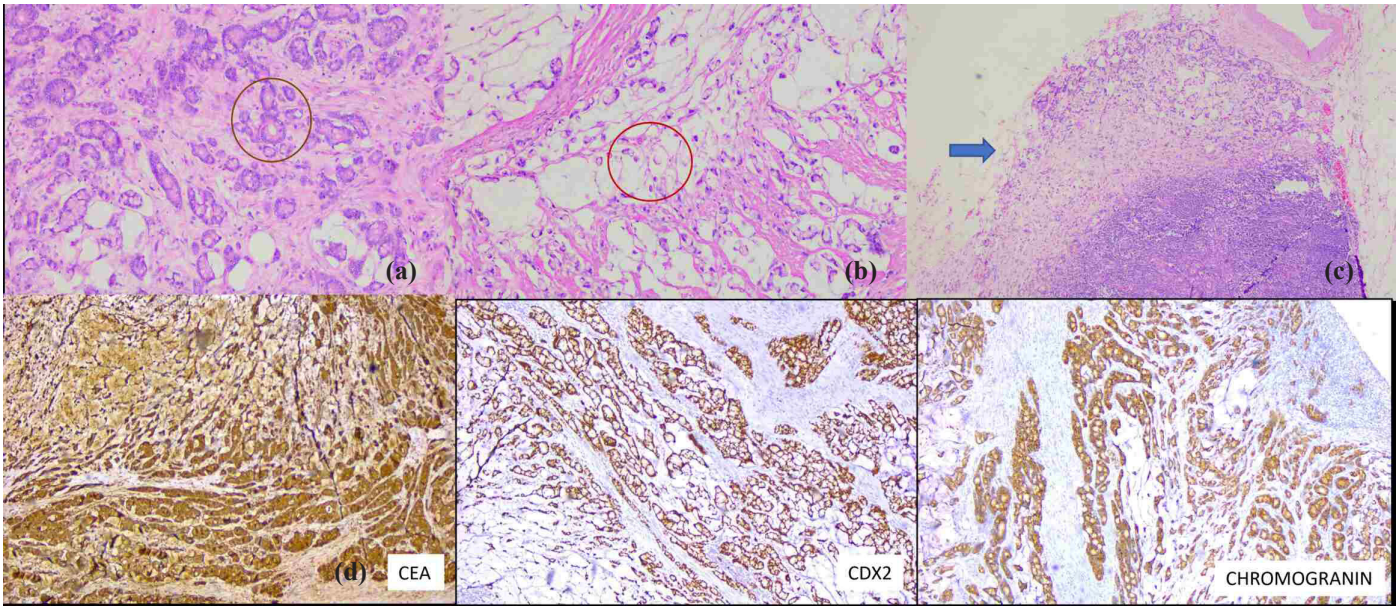

Fig.3 (a,c): *Microscopy showing neoplastic cells arranged as tubules, nests and trabeculae resembling intestinal crypts,* **(d):** *Neoplastic cells also exhibits diffuse positivity for CEA, CDX2 and Chromogranin.*

© 2025 Journal of Case Reports

Organization in 2010 designated only appendiceal amphicrine neoplasms as goblet cell carcinoids. In non-appendiceal gastrointestinal tract tumors, the use of different terminologies often leads to additional confusion, resulting in misdiagnosis and inappropriate treatment [1].

Amphicrine cells are observed in normal tissues as well as dysplastic lesions. These bivalent cells, derived from the endoderm, are the predominant cell type in amphicrine carcinoma [2]. Genetic studies of gastro-intestinal MANECs shows that amphicrine carcinomas represent the malignant proliferation of multivalent stem cells supporting the notion of stem cells in the stomach where amphicrine carcinomas have been previously documented [2]. The morphologic features of the amphicrine component appears to be similar to previous reports of stomach neoplasms. Similar to our case, amphicrine carcinoma of the stomach is arranged in a classic carcinoid pattern of solid nests and tubules and exhibits biphasic differentiation by electron microscopy [3].

Amphicrine carcinomas have been documented in various organs, such as skin, larynx, lung, gastrointestinal tract, pancreas, thyroid, breast, uterine cervix, vulva and prostate [4]. Microscopically, the tumors produce mucin or glandular structures ranging from 10% to more than 70%, in cells positive for chromogranin [5]. Most patients present with abdominal pain, which is also the common symptom in this study. Diagnosis is difficult with ultrasound or CECT, and there are no standard management guidelines due to limited case series. Treatment depends on symptoms, tumor location, grade, and Ki67 index. These tumors generally behave less aggressively and have better outcomes versus other tumors in similar locations. Tumor grade is a major factor in clinical presentation and prognosis. Most patients undergo surgical resection, and mean overall survival varies from 11 to 40 months [1]. Our study showed a survival of 11 months without any recurrence and the patient received adjuvant CAPEOX chemotherapy. Adjuvant chemotherapy has a low threshold if metastasis is present. In over seven reports, 22 cases of colorectal amphicrine cancers with metastasis have been described. Three patients were treated with palliative chemotherapy [6]. In one study, FOLFOXIRI has shown partial response as adjuvant therapy for metastatic rectal amphicrine cancer with progression free survival of 8.7 months. However, overall survival was only 16.0 months indicating that amphicrine cancer has a worse prognosis than colorectal adenocarcinoma [6].

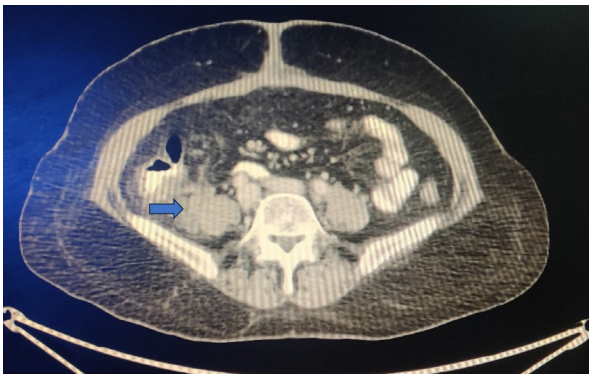

Fig.4: *Contrast enhanced computed tomography shows disease recurrence at previous anastomotic site (arrow).*

Conclusion

Amphicrine carcinoma of the small bowel is a rare diagnostic challenge that requires careful pathological evaluation. Reporting such cases is vital to improve recognition, guide management, and build evidence for future therapeutic decisions.

Contributors: HS: concept and manuscript writing; HR: manuscript revision; AS: manuscript writing and literature search; AME: manuscript writing and histopathology. HS will act as a study guarantor. All authors approved the final version of this manuscript and are responsible for all aspects of this study.

Funding: None; *Competing interests*: None stated.

References

1. Huang D, Ren F, Ni S, Tan C, Weng W, Zhang M, *et al*. Amphicrine carcinoma of the stomach and intestine: a clinicopathologic and pan-cancer transcriptome analysis of a distinct entity. Cancer Cell Int. 2019;19:310.

© 2025 Journal of Case Reports

2. Ludmir EB, McCall SJ, Cardona DM, Perkinson KR, Guy CD, Zhang X. Mixed adenoneuroendocrine carcinoma, amphicrine type, of the small bowel. Am J Clin Pathol. 2016;145(5):703-709.
3. Yang GCH, Rotterdam H. Mixed (composite) glandular-endocrine cell carcinoma of the stomach. Report of a case and review of literature. Am J Surg Pathol. 1991;15(6):592-598.
4. Mándoky L. Amphicrine tumor. Pathol Oncol Res. 1999;5(3):239-244.
5. Serra S, Chetty R. Amphicrine (mixed adenoneuroendocrine carcinoma) of the duodenum and coexistent metastatic well differentiated neuroendocrine tumour. Diagnostic Histopathology. 2014;20(7):297-300.
6. Tamura N, Honma Y, Sekine S, Tsukamoto S, Hirano H, Okita N, *et al*. Potential treatment of metastatic amphicrine carcinoma of the rectum with FOLFOXIRI chemotherapy. Oxf Med Case Reports. 2020;2020(11):omaa097.

© 2025 Journal of Case Reports