An Unusual Variant of a Syndrome Associated with Hypospadias

Anup Kumar, Pawan Vasudeva, Harbinder Singh, Gaurav Kumar, Rohit Kumar, Sanjeev Kumar Jha
Department of Urology, VMMC & Safdarjung Hospital, New Delhi-110029, India.

Abstract:

Smith-Lemli-Optiz syndrome (SLOS) is an inherited autosomal recessive disorder resulting from defect in cholesterol synthesis due to deficiency of enzyme 7-dehydrocholesterol reductase (7-DHC). SLOS is characterized by mental retardation and associated multiple congenital anomalies including microcephaly, dismorphic facial features, syndactaly, polydactaly, hypospadias, cryptorchidism, micropenis, pelvi-ureteric junction obstruction, renal agenesis, cardiac defects (ASD, PDA, VSD etc.). Patients may also have multiple gastrointestinal, central nervous system and endocrine abnormalities. We present an unusual, unreported variant of SLOS presenting as penoscrotal hypospadias with congenital perineal hernia, multiple mesenteric lipomas in addition to other usual features of the syndrome.

Key words: Genital Diseases, Hypospadius, Smith-Lemli-Optiz Syndrome, Urogenital Abnormalities, Kidney Diseases.

Introduction

Hypospadias is an abnormality in penile development that results in the urethral meatus being proximal to its normal glanular position [1]. The ectopic urethral openings (meatus) can be glanular, coronal, subcoronal, penoscrotal, scrotal, or perineal [2]. The reported incidence of hypospadias is 1:300 and is associated with ventral curvature of the penis (chordee), a hooded incomplete prepuce, and an abortive corpora spongiosum [3]. There are more than 200 different syndromes associated with hypospadias and Smith-Lemli-Optiz syndrome is one of them [4]. We are reporting a variant of this syndrome associated with congenital perineal hernia, absent kidney, multiple mesenteric lipomas and multiple other anomalies not reported before.

Case Report

13 year old male child presented with complaints of passage of urine from undersurface of penis and swelling in perineal region since birth, with history of delayed milestones. On examination patient had prognathism and protruding teeth, extra toe in each foot and left sided limp. Local examination revealed penoscrotal hypospadias, chordee and bilateral normal testis. There was a herniated loop of gut lying between the normally situated anal opening and urethral meatus with congested

Corresponding Author: Dr. Harbinder Singh
Email: drhbali@rediffmail.com
Received: February 24, 2015 | **Accepted:** April 24, 2015 | **Published Online:** May 15, 2015

Conflict of interest: None declared | **Source of funding:** Nil | **DOI:** http://dx.doi.org/10.17659/01.2015.0052

and inflammed mucosa [Fig.1]. On digital rectal examination, there was no communication between rectum and herniating bowel loop.

Patient was investigated and ultrasound abdomen revealed non-visualized left kidney. MRI abdomen and pelvis showing absent left levator ani muscle leading to perineal hernia and non-visualized left kidney. DMSA scan revealed absent left kidney and right kidney glomerular filtration rate of 86.7 mL/min. Micturating cystourethrogram was normal. In view of multiple anomalies karyotyping was done which revealed 46 XY and absence of AZF PCR micro deletion. With these findings a diagnosis of penoscrotal hypospadias with agenesis of left levator ani with perineal hernia with left renal agenesis (with associated multiple congenital anomalies: polydactyly, microcephaly, dysmorphic facial features): a variant of Smith-Lemli-Optiz syndrome was made that was confirmed by 7-dehydrocholesterol reductase (DHCR) mutation and lipid profile showing low cholesterol and high dehydrocholesterol (DHC).

Patient underwent perineal hernia repair (the herniated loop was a duplicated gut loop lying parallel to sigmoid colon which was excised) via combined abdomino-perineal approach, pelvic floor reconstruction using Gracilis muscle [Fig.2,3] and staged buccal mucosal graft urethroplasty and chordee correction. On follow up patient is doing well.

Discussion

The prevalence of Smith-Lemli-Optiz Syndrome has been reported to be 1 in 20,000 with equal preponderance in male and female [5]. Smith-Optiz-Lameli syndrome is an autosomal recessive disorder resulting from defect in cholesterol biosynthesis due to deficiency of enzyme 7-dehydrocholesterol reductase (DHCR-7), leading to abnormally

Fig.1: Penoscrotal hypospadias with perineal hernia.

Fig.2: Intraoperative photograph showing duplicated bowel loop continuing down in perineal hernia sac.

low plasma cholesterol and markedly elevated 7-dehydrocholesterol. DHCR gene is located on chromosome 11q11-13 [5,6]. SLOS is characterized by mental retardation and associated multiple congenital anomalies including microcephaly, dismorphic facial features, syndactaly, polydactaly, hypospadias, cryptorchidism, micropenis, pelvi-ureteric junction obstruction, renal agenesis, cardiac defects (ASD, PDA, VSD etc.) [5]. Patients may also have multiple gastrointestinal, central nervous system and endocrine abnormalities.

Two phenotypes of SLOS have been described, type-1 (mild) and type-2 (severe). Patients with severe form of SLOS often die in perinatal period. Some patient with mild form of SLOS have been identified with border line normal IQ whereas majority have global intellectual disability. Behavioral abnormalities in SLOS include sleep disturbances, irritability, aggressiveness, autism and self-injuring activity [7]. The simplest and most convenient method for diagnosis of SLOS is measurement of plasma level of 7-DHC and cholesterol with DHCR-7 mutation testing being confirmatory.

Treatment trials are under way. Dietary cholesterol supplementation has become standard of care. HMG-CoA reductase inhibitors (statins) have also been evaluated in various trials. Surgical interventions to correct congenital anomalies are often needed.

Conclusion

Although Smith-Lameli-Optiz syndrome is a rare syndrome associated with hypospadias, it must be kept in mind in a patient presenting with multiple anomalies along with hypospadias. The simplest method for diagnosis of SLOS is measurement of plasma level of 7-DHC and cholesterol with DHCR-7 mutation testing being confirmatory.

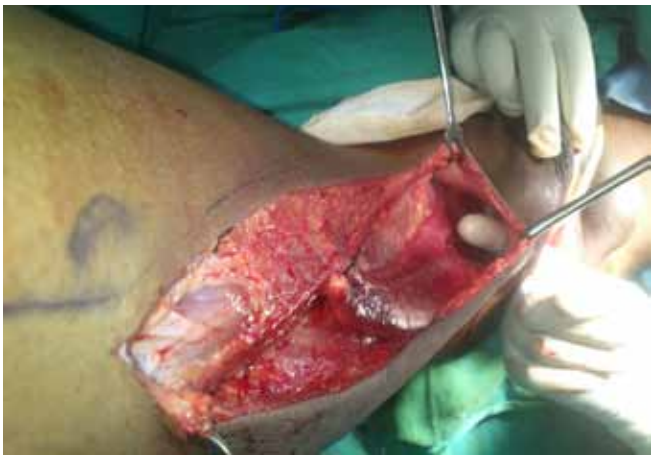

Fig.3: Intraoperative photograph showing pelvic floor reconstruction with gracilis muscle.

Surgical interventions are often needed to correct congenital anomalies.

References

1. Kraft KH1 , Shukla AR, Canning DA. Hypospadias. Urol Clin North Am. 2010;37:167-181.
2. Djakovic N, Nyarangi-Dix J, Özturk A, Hohenfellner M. Hypospadias. Advances in Urology 2008 (2008), Article ID 650135.
3. Perovic S (eds). Atlas of Congenital Anomalies of the External Genitalia. Refot-Arka: Belgrad, Yugoslavia; 1999.
4. Snodgrass W. Hypospadius. *In*: Campbell-Walsh Urology Eleventh Edition. Elsevier, 2012, pp. 97-101.
5. Jones KL, Smith DW. Smiths recognizable pattern of human malformation. 6th ed.Philadelphia:Sunders;2005.
6. Iron M, Elias ER, Salen G, Tint GS, Batta AK. Defective cholesterol biosynthesis in Smit- Lemli-Optiz syndrome. Lancet.1993;341:1414.
7. Andrea E DeBarber, Yasmeen Eroglu, Louise S, Merkens, Anuradha S Pappu, Robert D. Steiner. Smith-Lemli-Optiz Syndrome. Expert Rev Mol Med. 2011;13:e24.