JOURNAL OF CASE REPORTS 2015;5(1):271-273

Post traumatic Pseudocyst of Liver

Deen Dayal Sharma, Arvind K Shukla, Vinita Chaturvedi, Mahendra Jangid, Gurudatt Raipuria
Department of Paediatric Surgery, S.M.S. Medical College & associated SPMCHI, Jaipur, Rajasthan, India.

Abstract:

We report a case of an eighteen month old female child, who presented with abdominal pain, swelling and failure to thrive with history of blunt trauma abdomen in road traffic accident, two months back. Ultrasonography and computed tomography scan (CT scan) whole abdomen, showed a large cystic swelling behind and inferior to liver with collection in lesser sac. External drainage was done after aspiration of cyst having volume of 1500 mL which was bile stained, with successful outcome.

Key words: Cysts, Drainage, Abdominal Injuries, Liver, Accidents, Pain.

Introduction

The liver is one of the commonest organ injured organ in blunt abdominal trauma. Most often liver trauma results only in superficial lacerations [1]. Traumatic liver cysts are unusual sequel of hepatic trauma [2]. The commonest variety of liver cyst is congenital type and the acquired type may be inflammatory, neoplastic or traumatic. This case represents a typical natural history of post traumatic cyst of the liver. Symptomatic post traumatic cysts of liver have an incidence of less than 0.5% among all liver cysts [3]. We have found only few case reports of post traumatic liver pseudocyt in paediatric age group [2-4, 9] and in our best of knowledge, this is the third case report of this entity from India.

Case Report

An eighteen month old female child presented with complaints of huge abdominal swelling involving almost whole of the abdomen with dull aching pain and failure to thrive. Two months back, she had a road traffic accident causing blunt abdomen trauma over upper abdomen. Patient was admitted in hospital with stable vitals. CT abdomen showed small laceration in right lobe of liver. Patient was treated conservatively and discharged after five days. Repeat abdominal CT scan done after ten days, showing resolving hematoma, in right lobe of liver with hepatomegaly. After a month, patient presented to us, with above mentioned symptoms.

Corresponding Author: Dr. Deen Dayal Sharma
Email: drddsharma@rediffmail.com
Received: April 4, 2015 | **Accepted:** May 29, 2015 | **Published Online:** June 25, 2015

Conflict of interest: None declared | **Source of funding:** Nil | **DOI:** http://dx.doi.org/10.17659/01.2015.0069

Clinical examination showed a huge rounded swelling of 10x12 cm size, involving almost whole of the abdomen, cystic to firm in consistency with mild tenderness. A provisional diagnosis of post traumatic pseudo pancreatic cyst was made. Complete blood counts and biochemistry were within limits with marginally raised serum amylase. CT scan abdomen demonstrated a large lobulated cystic lesion, 10x11x15 cm of size extending from anterio-inferior surface of liver to pelvis, suggesting differential diagnosis as loculated fluid collection, pseudo-pancreatic cyst, mesenteric cyst and lymphangioma along with old haematoma in segment 8 of liver.

The patient was operated for exploratory laparotomy through right sided supra-umbilical incision which was extended across the midline, revealing large cystic mass under the surface of left lobe of liver, stretching the liver up to left iliac region. 1500 ml of bile stained fluid was aspirated with placement of drain inside the collapsed cavity of cyst after complete aspiration. However, no communication was found with biliary radical. The other organs like stomach, transverse colon and pancreas were free from the cyst. Post-operatively, 10-20 ml serosanguineous fluid came out in the drain for first few days, which stopped gradually. The child is maintaining well till last follow up done 2 months back.

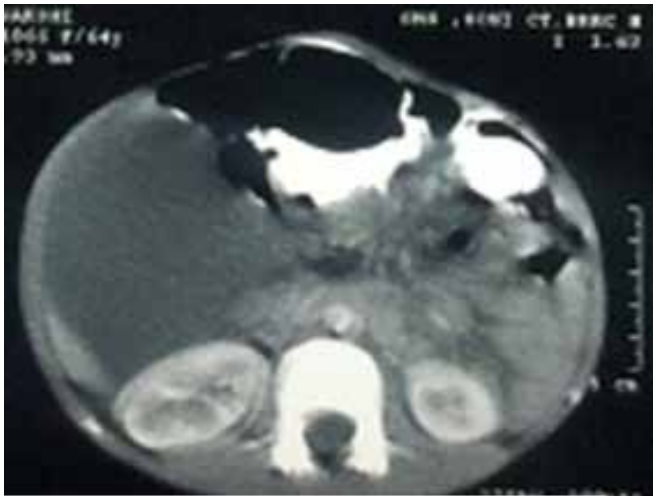

Fig.1: CT scan abdomen (transverse plane) showing a large cyst involving liver.

Fig.2: Intra-operative aspiration of bile stained fluid.

Discussion

Acquired hepatic cyst is less common than the congenital variety and may be inflammatory, neoplastic or traumatic. Symptomatic post traumatic cyst of liver is amongst the less frequently known sequel of liver injury. The incidence of this condition is less than 0.5 percent [3]. Reviewed literature shows only few case reports of post traumatic liver pseudocyt in paediatric age group till date [2-4,9]. Abdominal pain, distension and hepatomegaly are the most common presenting features as described in the literature. Rarely cases present with the complications like obstructive jaundice, abscess formation, hemorrhagic shock or biliary peritonitis due to rupture of cyst [2,3,5]. The present case presented with abdominal distension and hepatomegaly.

Christopher had classified liver injury into three types- central, sub capsular and rupture with its capsule [1]. It is central or intrahepatic type of variety which is associated with this complication in which there is oozing of blood and bile. Blood stops oozing and bile continues to flow, resulting in growth of cyst. Therefore, there is usually a delay of several weeks to several months after hepatic trauma, before the patient becomes symptomatic [2,4,5]. Many workers, who described post traumatic liver cyst, did so in pre-imaging era. It was Sugimoto *et al*. in 1982 who emphasized the role of CT scan for diagnosis of liver Injuries [3]. He also highlighted the importance of serial CT scan in diagnosis of such cases.

The differential diagnosis of a post traumatic liver cyst clinically and at imaging includes a solitary unilocular cyst, hydatid cyst, a psedopancreatic cyst and loculated ascites especially due to tuberculosis [7]. In a post-traumatic cyst, altered blood and bile are the chief constituents. Definitive diagnosis at histopathology is based on recognizing absence of a true epithelial lining, which is present in unilocular hepatic cyst [2].

Treatment modalities employed for these cysts include simple drainage, marsupilisation, decortications and omentoplasty [4] and capitonnage for larger cysts [9]. Recently these lesions have been safely treated by laparoscopic excision and by ultrasound guided percutaneous drainage using supra-cath. In few cases partial hepatic resection [3,10] were needed while in few cases spontaneous resolution has also been reported.

Conclusion

A serial clinical examination followed by imaging is essential to monitor post traumatic liver injuries and its complications.

References

1. Christopher F. Rupture of the liver. Ann Surg. 1936;103:461-464.
2. Henson SW Jr, Gray HK, Dockerty MB. Benign tumors of the liver. V Traumatic cysts. Surg Gynaec Obs. 1957;104:302-306.
3. Sugimoto T, Yoshioko T, Sawada Y, Sugimoto H, Maemura K. Post traumatic cyst of the liver found on CT scan-A new concept. J Trauma. 1982;22:797-800.
4. Chuang JH, Huang SC. Post traumatic hepatic cyst- an unusual sequel of liver injury in the era of imaging. J Pediatr Surg. 1996;31:272-274.
5. Jones HV, Harley HR. Traumatic cyst of the liver. Br J Surg. 1970;57:468-470.
6. Walt AJ. Cyst and benign tumors of the liver. Surg Clin North Am. 1977;57:449-464.
7. Peltokallio V. Non parasitic cysts of the liver-A clinical study of 117 cases. Ann Chir Gynecol Fenn. 1970;59:1-63.
8. Wu X, Tan JZ, Shi TH, Zhou SN. Open method versus capsulorraphy without drainage in the treatment of children with hepatic hydatid disease. Br J Surg. 1992;79:1184-1186.
9. Simmi K Ratan, Grover SB. Post-Traumatic Hepatic cyst. Indian Pediatrics. 1999;36:1048-1051.
10. Singh KK, Nizarudeen A. Post-Traumatic (Haemorrhagic) Liver cyst. Indian J Surg. 2013;425-427.