Black Stomach

John Grifson J, Perungo T, Amudhan A, Bennet D, Prabhakaran R, Chandramohan SM, Anand L, Kannan DG
Institute of Surgical Gastroenterology, Rajiv Gandhi Government General Hospital and Madras Medical College, Chennai, India.

Abstract:

Acute gastric necrosis resulting in a black stomach is a very rare occurrence. We report a young male with corrosive ingestion who was referred to us in a moribund state. At laparotomy he was found to have a tarry black stomach due to necrosis. He recovered following total gastrectomy. To the best of our knowledge this is the first case report of black stomach.

Key words: Caustics, Gastrectomy, Laparotomy, Stomach Diseases.

Introduction

Injury to stomach and oesophagus is a significant cause of morbidity after corrosive ingestion. Acid tends to produce more gastric injury because of the coagulative necrosis which damages the dependent areas of stomach like antrum. Acute gastric necrosis resulting in a black stomach is a very rare occurrence. To the best of our knowledge this is the first reported case of black stomach.

Case Report

A 34 year old man was referred to us with worsening abdominal pain and respiratory distress. On examining he was toxic, tachypneic and dehydrated. His pulse rate was 142/min and respiratory rate was 26/min with a SpO_2 of 98%. Review of his history revealed that he had consumed about 300 ml of toilet cleaning acid (hydrochloric acid) mixed with alcohol 2 days before in view of family dispute. Examination of oral cavity revealed severe mucosal injury with ulcers. There was severe bilateral coarse crepitation in both the lung fields. Abdominal examination revealed severe guarding and rigidity in the upper abdomen and a relatively soft lower abdomen.

Laboratory investigations revealed a total WBC count of 14,000/mm^3 with left shift. Arterial blood gas analysis showed severe acidosis with a pH of 7.23. Patient was resuscitated and rehydrated. Computer tomography imaging revealed oedematous stomach wall with intramural air [Fig.1]. Patient underwent emergency laparotomy. Intra-operatively there was no evidence of perforation. The duodenum appeared healthy and small bowel was loaded with black contents as seen in luminal

Corresponding Author: Dr. John Grifson
Email: johngrifsondr@gmail.com
Received: November 20, 2015 | **Accepted:** January 6, 2016 | **Published Online:** January 30, 2016
This is an Open Access article distributed under the terms of the Creative Commons Attribution License (creativecommons.org/licenses/by/3.0)
Conflict of interest: None declared | **Source of funding:** Nil | **DOI:** http://dx.doi.org/10.17659/01.2016.0012

bleeding. The stomach was gangrenous and greyish black in appearance. The distal oesophagus showed ulceration but was not necrotic. Patient underwent total gastrectomy. The distal oesophagus was diverted by inserting a Foley's catheter into the distal oesophagus and the distal end was closed over the Foley's with a purse string. A feeding J tube was placed by modified Whitzel's technique. The cut section of stomach showed thickened gastric wall with dark tarry black gastric mucosa [Fig.2]. His post-operative period was stormy and he was on ventilatory and inotropic support. After seven days of intensive care and ventilator support he gradually recovered.

Discussion

Corrosive ingestion is still a common problem in developing countries. Adult patient who suffer from this complex problem usually consume corrosives with suicidal indention, whereas in children it is accidental [1]. The extent of damage and complications depend upon the (i) type and amount of substance consumed (ii) if the substance is consumed alone or diluted (iii) whether consumed in empty or full stomach and (iv) duration of contact. Although acute oesophageal necrosis and rare complications like tracheal perforation [2] and liver necrosis [3] have been described in the literature, acute gastric necrosis is relatively rare because a high volume and concentration of corrosive is required to produce such a severe damage. Black stomach due to acute gastric necrosis carries a high mortality and morbidity. Coagulative necrosis of mucosa results in intramucosal haemorrhage and acid hematin deposition producing the tarry black colour. Even though surgery is inevitable, performing emergency surgery in such a situation has been found to negatively impact the survival and outcome [4]. In the presence of extensive necrosis, CT scan has been proved to be better aid to decide about the need of surgery [5]. At any cost rather timely and early surgery may be the only hope of survival in such moribund patients.

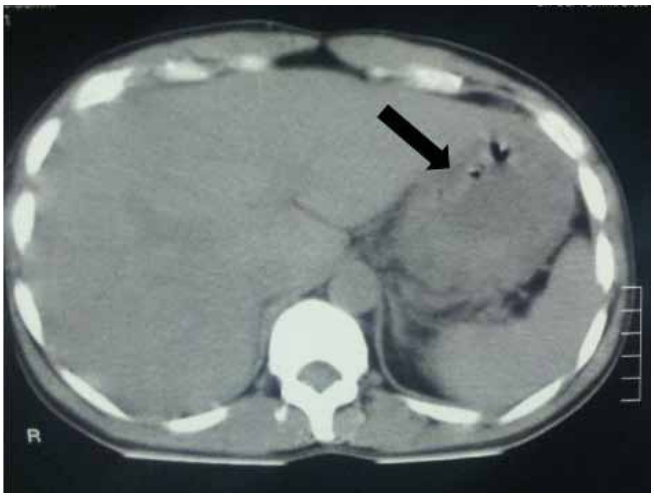

Fig.1: CT scan of abdomen showing oedematous stomach wall with intramural air suggestive of necrosis.

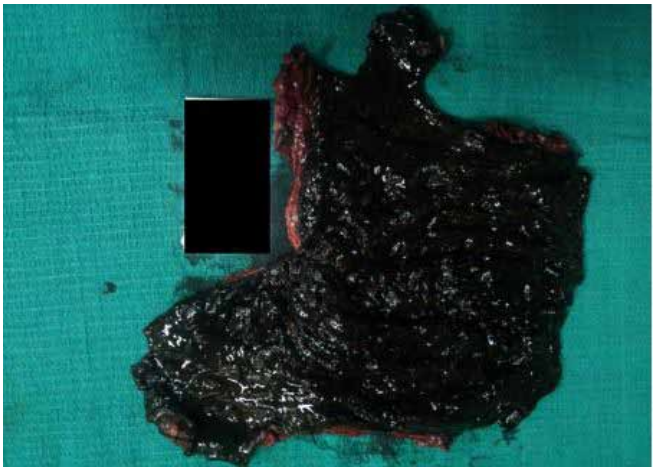

Fig.2: Resected total gastrectomy specimen showing gangrene with tarry black staining and necrosis of mucosa.

Conclusion

To the best of our knowledge this is the first report of "Black stomach" in the literature. Urgent total

gastrectomy, esophageal diversion, feeding tube placement and aggressive intensive support were the essential tools of survival in our patient.

References

1. Watson WA, Litovitz TL, Rodgers GC, Klein-Schwartz W, Reid N, Youniss J, *et al*. 2004 Annual report of the American Association of Poison Control Centers Toxic Exposure Surveillance System. Am J Emerg Med. 2005;23:589-666.
2. Chen KC, Hsiao CH. Tracheal perforation in esophageal corrosive injury. Ann Thorac Surg. 2013;96(5):1879.
3. Javed A, Yanger N, Agarwal AK. Liver necrosis following corrosive ingestion. Indian J Gastroenterol. 2014;33(1):77-78.
4. Sandro Contini, Carmelo Scarpignato. Caustic injury of the upper gastrointestinal tract: A comprehensive review. World J Gastroenterol. 2013 ;19(25):3918-3930.
5. Ananthakrishnan N, Parthasarathy G, Kate V. Acute corrosive injuries of the stomach: a single unit experience of thirty years. ISRN Gastroenterol. 2011;2011:914013.