A Curious Case of Mullerian Origin Retroperitoneal Cyst

Manoj Gopal Madakshira[1], Vikram Singh[2]
Department of Pathology, [1]Armed Forces Medical College, Pune, and [2]Military Hospital, Ahmednagar, Maharashtra, India.

Abstract:

Retroperitoneal cysts are unusual group of lesions, with diverse morphologies which range from a pancreatic pseudocyst to cystic teratoma. The wide range of etiologies makes histopathology of the excised cyst mandatory to ascertain the non-neoplastic or neoplastic nature of the lesion. Amongst the lesions, Mullerian cysts of retroperitoneum are very rare and known to arise from Mullerian rests which are sensitive to hormonal influence.

Key words: Ascites, Cysts, Pain, Peritoneal Neoplasms, Postmenopause, Retroperitoneal space.

Introduction

Retroperitoneal cysts are uncommon lesions which can be both neoplastic and non neoplastic. Neoplastic lesions include cystic lymphangioma, mucinous cyst adenoma, cystic teratoma, cystic mesothelioma, mullerian cyst, epidermoid cyst, bronchogenic cyst, cystic change in solid neoplasms and pseudomyxoma retroperitonei. Non-neoplastic lesions can be pancreatic pseudocyst, non-pancreatic pseudocyst and lymphocele. Mullerian cyst of the retro peritoneum is an extremely rare condition and only few case reports are published [1,2].

Case Report

A 58 year postmenopausal, obese woman, gravida 2, para 2 presented with history of pain left lower abdomen of six months duration. There was no past history of menstrual irregularities or receiving hormonal treatment. Clinically, she had a non-tender lump in the left iliac region measuring 8x7 cm size. There was no evidence of ascites.

On ultra-sonogram (USG) correlation, left ovary was not seen separately. On Computerised Tomography (CT) scan, a retroperitoneal soft tissue oval mass, measuring 10x8x7.5 cm, with poor enhancement was seen in left lumbar region extending into left adenexal region [Fig.1A]. There was no evidence of any pancreatic lesion, ascites and adenopathy. A serum amylase level was normal (100 U/L). Other tumour markers i.e. serum cancer antigen (CA) 125, alpha fetoprotein (AFP), lactate dehydrogenase (LDH), β human chorionic gonadotropin (HCG) levels were also within normal limits. Based on the clinical and radio-imaging

Corresponding Author: Manoj Gopal Madakshira
Email: manoj.gopal@gmail.com
Received: February 25, 2016 | **Accepted:** May 31, 2016 | **Published Online:** July 20, 2016

Conflict of interest: None declared | **Source of funding:** Nil | **DOI:** http://dx.doi.org/10.17659/01.2016.0081

findings, preoperative diagnosis of left ovarian cyst was considered and patient was taken up for surgery.

Intra-operatively a retroperitoneal cyst was found close to descending colon and left of abdominal aorta. Cyst measured approximately 12x8x7 cm in size, displacing left ureter laterally. All the abdominal organs including both the ovaries were separate from the cyst wall and grossly normal [Fig.1B]. Cystectomy was performed [Fig.1C-D]. Cyst was multiloculated with serous content. The inner surface was smooth without any papillary projections. Histopathological examination (HPE) of the excised cyst showed a cyst lined by ciliated cuboidal to low columnar epithelium without any atypia, similar to the tubal lining [Fig.2A]. Lining epithelium showed immunopositivity for cytokeratin (CK) 7, estrogen receptor (ER), progesterone receptor (PR) and epithelial membrane antigen (EMA). It showed immunonegativity for CK 20, CD34 and Calretinin. [Fig.2B-2F]. Post-operative period was uneventful.

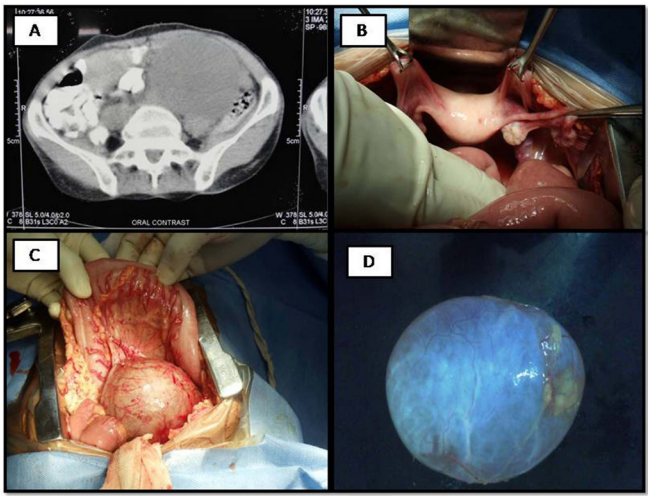

Fig.1:(A) CT image showing retroperitoneal soft tissue oval mass, seen in left lumbar region extending into left adenexal region. **(B)** Intraoperative image showing both the ovaries and fallopian tubes free of cyst wall. **(C)** Intraoperative image of the cyst. **(D)** Gross image of the excised cyst.

Discussion

Retroperitoneal cysts often cause diagnostic dilemma. One of the studies found correct preoperative diagnosis in only 25% of cases [3]. Mullerian cyst of the retro peritoneum occurs in women from 19 to 47 years of age especially in obese woman who had received hormonal treatment [4]. Exact pathogenesis of these lesions is still not well known. One of the possibility is that, retroperitoneal tissue may have an aberrant mullerian duct remnant, which might have a capacity for growth in the presence of abnormal hormonal stimuli. Lee J *et al*. [1] asserted that hormonal stimuli influenced the growth of mullerian cyst because they observed most patients received hormonal treatment for menstrual irregularities.

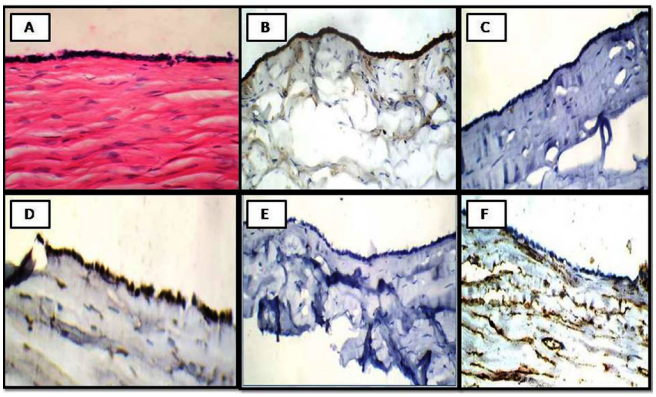

Fig.2:(A) Photomicrograph of H & E stain section of excised retroperitoneal cyst (100x) lined by ciliated cuboidal to low columnar epithelium without any atypia **(B)** Photomicrograph of IHC staining with CK7 **(C)** CK 20 **(D)** ER **(E)** calretinin **(F)** CD 34.

In present case presence of normal ovaries, ciliated tubal like epithelial lining of the cyst wall and immunohistochemistry analysis supported diagnosis of mullerian cyst as described by Konishi E *et al*. [5]. One more possibility was developmental anomalies like duplication of mullerian duct leading to this kind of lesion but absence of any other associated anatomic abnormality of urogenital organs ruled out such a possibility.

To conclude, retroperitoneal mullerian cyst should be kept in mind if histopathological examination shows epithelial lining similar to fallopian tubes. Cystectomy is curative in these cases and correct diagnosis can prevent any possible radical surgery.

References

1. Lee J, Song SY, Park CS, Kim B. Mullerian cysts of the mesentery and retro peritoneum: a case report and literature review. Pathol Int. 1998;48:902-906.
2. De Peralta MN, Delahoussaye PM, Tornos CS, Silva EG. Benign retroperitoneal cysts of mullerian type: a clinicopathologic study of three cases and review of the literature. Int J Gynecol Pathol. 1994;13(3):273-278.
3. Kurtz RJ, Heimann TM, Beck AR , Holt J. Mesenteric and retroperitoneal cysts. Ann Surg. 1986;203:109-112.
4. Steinberg L, Rothman D, Drey NW. Mullerian cyst of retroperitoneum. Am J Obstet Gynecol. 1970;107:963-964.
5. Konishi E, Nakashima Y, Iwasaki T. Immunohistochemical analysis of retroperitoneal Mullerian cyst. Hum Pathol. 2003;34:194-197.