JOURNAL OF CASE REPORTS 2016;6(4):580-582

Huge Mature Cystic Teratoma in a Nulliparous Patient

İlhan TAŞDÖVEN, Muzaffer Önder Öner
Department of General Surgey, Van Training and Research Hospital, Van, Turkey.

Abstract:

Background: Mature cystic teratomas are generally asymptomatic and have benign characters. They are most frequently observed in women during reproductive ages. Although the ones bigger than 10 cm are rare because they grow slowly, a giant mature cystic teratoma (approx. 35 cm) was detected in our patient, and she has been presented here as a case study. *Case Report*: A 27-year-old nulliparous female applied to our clinic with abdominal mass and distension. She was operated with the diagnosis of mature cystic teratoma. *Conclusion*: Nowadays, the prevalence of mature cystic teratomas that reach big masses has been reduced with the development of imaging methods in developed countries. Mature cystic teratomas must be born in mind during the distinctive diagnosis in abdominal masses. They can rarely reach giant size without giving serious clinical findings. During surgery and post-operative followups, fluid gap and hemodynamic changes must be closely monitored.

Key words: Calcification, Dermoid Cyst, Laparotomy, Parturition, Teratoma.

Introduction

In general surgery, distension of the abdomen is observed frequently. Despite the various differential diagnoses, the existing diagnosis methods may only be trusted with a radiological imaging. Ovarian lesions may appear with palpable abdominal mass, abdominal pain, urinary obstruction and ileus. Mature cystic teratomas stem from germ cells and include three embryonic germ layer structures. Mature cystic teratomas are the most frequent ones among the ovary teratoma. They constitute 15% of all the ovarian tumors [1].

Majority of teratomas are benign tumors with increased incidence seen between 30-40 years of age. They generally progress insidiously without any symptoms, and sometimes can reach giant size and volumes in clinical terms. They are observed as bilateral in 10-15% [1,2]. Giant ovarian masses may cause pressure symptoms in intra-abdominal organs and structures. Hypotension due to volume loss with mass excision, and hemodynamic complications like low hemoglobin levels may be observed in patients with giant ovarian mass as it is the case in patients with big abdominal mass [3].

Case Report

27-year-old nulliparous patient applied to our general surgery clinic with abdominal mass and

Corresponding Author: Dr. İlhan TAŞDÖVEN
Email: gulinergun@gmail.com
Received: July 21, 2016 | **Accepted:** October 14, 2016 | **Published Online:** December 15, 2016

Conflict of interest: None declared | **Source of funding:** Nil | **DOI:** http://dx.doi.org/10.17659/01.2016.0142

distension. In the anamnesis it was learnt that the mass was there since her childhood. Approximately 35 cm mass lesion was handled in abdomen palpation. A solid mass, which nearly filled the whole abdomen, was detected in ultrasound. The biochemical and coagulation parameters of the patient were determined to be normal. In the whole abdomen tomography, a 26x19.5x28 cm mass lesion was detected in umbilical and epigastric region with irregular calcification in the right lateral wall. Lobulated contour components which are in fat density in some areas and the multiplea morphous nodular calcifications were detected in mass lesion [Fig.1]. The CA 15-3; CA 19-9; CA 125 values were determined in the patient. She was transferred to the gynecology department with the pre-diagnosis of giant teratoma stemming from adnexitis. The image of the abdomen of the patient in pre-operative period is shown Fig. 2. No congestive heart failure and venous obstruction findings were detected in the patient in the pre-operative period.

The patient was operated together with the general surgery and gynecology departments teams. In the laparotomy, 35x30 cm, 10.5 kg heterogeneous mass with intact capsule stemming from the right ovary with intestinal adhesions was detected. The intestines were separated with dissection over the mass. Salpingo-oophorectomy was applied together with the gynecology team. No hypotension and hypoxemia findings were detected in the patient during the surgery. The patient was discharged with recovery on 7th postoperative day. The pathology report of the patient revealed a cystic tissue which was 35 cm in diameter with 22x2 cm in size with oviducts. During the incision of incised mass, fluid came out of the cyst which included sebum and hairs. The wall thickness of the cyst was 0.3 cm and there was a 12x8x5 cm solid nodular area was observed in the internal side. It was reported that there were bone and fat tissue in the nodular area [Fig.3-4].

Fig.1: Mass lesion in the abdomen CT of the patient.

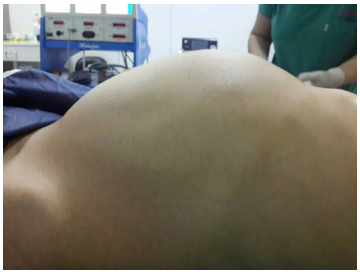

Fig.2: Patient in pre-operative period.

Fig.3: Excised ovarian tumor.

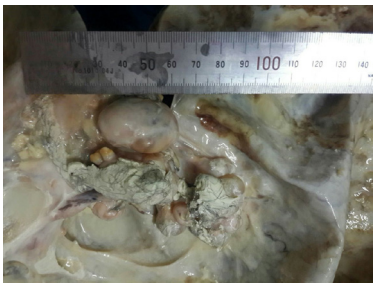

Fig.4: Tooth and hair follicles within the teratomas.

Discussion

The most common germ cell neoplasm is the mature cystic teratoma [4]. Many mature cystic teratomas are known to be asymptomatic. They grow at a slow speed (at an approximate rate of 1.8 mm/year). Most of the time, they have a size of about between 5 and 10 cm. They rarely reach a size that is more than 15 cm [1,5]. The mature cystic teratomas reach a very big size in extremely rare cases in clinical history [6,7]. There may be fat, sebaceous secretions, hair follicles, and hair in the cysts. In some cases (nearly 30%), there might also be structures resembling organs (teeth, bone fragments, etc.) [8]. Ultrasonography may help in diagnosing most of the mature cystic teratomas. In the CT scanning images, fat/fluid level attenuation, and calcification or ossification might be observed. The surgeons must be careful about the symptoms depending on the volume loss in the patient due to excision of the mass in giant-size ovary teratoma operations, just as it is the case in intra-abdominal masses. Multidisciplinary approach is necessary in the follow-up of the patient in intraoperative and postoperative period. The pre-operative hemoglobin value of our patient was 11 gm%, the intraoperative hemoglobin value was 8.3 gm%. The necessary replacement treatment was applied by the anesthesia team.

Majority are asymptomatic however, torsion, rupture, infection, and malignant change are also possible complications observed in ovarian teratoma. Malignant transformation is extremely rare (the prevalence is 1-2%), and squamous cell carcinoma is more common.

References

1. Comerci JT Jr, Licciardi F, Bergh PA, Gregori C, Breen JL. Mature cystic teratoma: a clinicopathologic evaluation of 517 cases and review of the literature. Obstet Gynecol. 1994;84(1):22-28.
2. Heint APM, Hacker NF, Lagasse LD. Epidemiology and etiology of ovarian cancer: A review. Obstet Gynecol. 1992;66:127.
3. Tagge DU, Baron PI. Giant adrenal cyst: management and review of the literature. Am Surg. 1997;63:744-746.
4. Koonings PP, Campbell K, Mishell Dr Jr, Grimes DA. Relative frequency of primary ovarian neoplasms: a 10-year review. Obstet Gynecol. 1989;74:921-926.
5. Ozgur T, Atik E, Silfeler DB, Toprak S. Mature cystic teratomas in our series with review of the literature and retrospective analysis: Archives of Gynecology and Obstetrics. 2012;285(4):1099-1101.
6. Chong HM, Lee FY, Lo A, Li CM. A giant gas-filled abdominal mass in an elderly female: a case report. World J Gastroenterol. 2011;17(31):3659-3562.
7. Devoize L, Collangettes D, Le Bouëdec G, Mishellany F, Orliaguet T, Dallel R, *et al*. Giant mature ovarian cystic teratoma including more than 300 teeth. Oral Surg. 2008;105:76-79.
8. Matz MH. Benign cystic teratomas of the ovary. Obstet Gynecol Surv. 1961;16:591-605.