

Grisel's syndrome: A Rare Non-traumatic Subluxation of Atlanto-axial joint

Param Harsh, K N Salimath¹, R S Negi², Amit Devgan

Departments of Pediatrics, ¹Otorhinolaryngology, ²Radiodiagnosis; 151 Base Hospital, Guwahati - 781029, Assam, India.

Corresponding Author:

Dr. Param Harsh

Email: mahajan_4952@yahoo.co.in

This is an Open Access article distributed under the terms of the Creative Commons Attribution License (creativecommons.org/licenses/by/3.0).

Received : August 24, 2017

Accepted : October 30, 2017

Published : November 15, 2017

Abstract

Background: Grisel's syndrome is a rare non-traumatic subluxation of atlanto-axial joint.

Case Report: We report a case of a 8 years old girl who presented with painful torticollis post adeno-tonsillectomy. A strong clinical suspicion followed by cervical CT and MRI examination confirmed the diagnosis. The conservative management approach using cervical collar resulted in excellent clinical outcome with resolution of subluxation on follow up. **Conclusion:** Early intervention and timely diagnosis can achieve full functional recovery with minimal neurological complications.

Keywords: Neck, Odontoid process, Quadriplegia, Joint Dislocations, Torticollis.

Introduction

In year 1830, Sir Charles Bell encountered death in a patient of pharyngeal ulcer. Subsequently his postmortem findings were suggestive of transverse ligament erosion due to laxity of C1 over C2 vertebra [1]. Later on Grisel, an ENT specialist from France demonstrated this rare entity among patients with nasopharyngeal pathology [2,3]. Although etio-pathogenesis of this entity is not clear, the clinicians should be acquainted with this condition to have a high index of suspicion and institute early intervention thereby leading to full functional recovery.

Case Report

A 8 year old girl underwent adeno-tonsillectomy for repeated episodes of upper respiratory infections. On second post-operative day, she developed mild fever (99°F) associated with neck pain and torticollis towards the right. There was no history of any neck trauma or previous head and neck surgery. Local examination of the right side of the neck revealed a soft tissue swelling with painful and restricted neck movements. The swelling was approximately 3×3 cm in size round to oval, fluctuant, mobile

without any features of inflammation and it was merging with underlying neck muscles. She had torticollis right (chin down and right) with spasm of cervical muscles associated with right shoulder droop. No local abscess or tender lymphadenopathy was palpable. Her oral examination including surgical wound site was normal. There was no neurological deficit on systemic examination and Sudeck's sign was negative.

Based on a clinical suspicion of Grisel's syndrome, CT scan of the cervical spine and a confirmatory MRI of the cervical spine were performed. It showed lateral displacement of the atlas over axis with increase distance between the odontoid and the lateral mass on the left side (4.4 mm) [Fig.1a]. On MRI examination the left alar ligament was intact but lax [Fig.1b]. No inflammatory changes were noted in the surrounding tissues or within the joint.

The patient was started on oral antibiotics (amoxicillin-clavulanic acid), paracetamol and muscle relaxants. She was also advised to wear cervical collar and have bed rest. She improved gradually over a period of 4 weeks without

neurological deficit when her treatment was discontinued. Cervical repeat CT and clinical examination showed complete regression of subluxation of C1-C2.

Discussion

Grisel's syndrome is a rare clinical entity associated with atlanto-axial joint subluxation without any underlying osteopathy. Although there are many theories about the pathogenesis of this entity it is believed that affection of the ligamentous stabilizers at the atlanto-axial joint lead to its causation. Instability of cervical spine may be attributable to laxity of transverse and alar ligaments secondary to inflammation [2,4]. In our case there was laxity of left alar ligament. Although any head and neck surgery can predispose to Grisel's syndrome but most common surgeries are mastoidectomy, tonsillectomy and adenoidectomy respectively. Infections of the upper respiratory tract and bony pathologies involving cervical spine should also be considered in the differential diagnosis [5]. In our case the condition was secondary to adenotonsillectomy.

As per the cited demography, Grisel's syndrome usually affects age group between 5 and 12 years with no sex predilection [1,2]. Children are especially prone due to pre-existing cervical ligament laxity and hypermobility of C1 on C2 [3]. Our patient was 8 years old and hence exactly fits into the demography of Grisel's syndrome. Patients mostly presents with pain neck, torticollis and restricted movements of cervical spine. A strong indicator of atlanto-axial subluxation is positive Sudeck's sign (sensitive palpable C2 spinous process). The spectrum of clinical presentation of Grisel's syndrome varies from case to case. Only less than 15 percent of patients will have neurological symptoms but in extreme case quadriplegia can result in serious morbidity and mortality [2].

Our patient had similar clinical presentation except Sudeck's sign was negative. Although

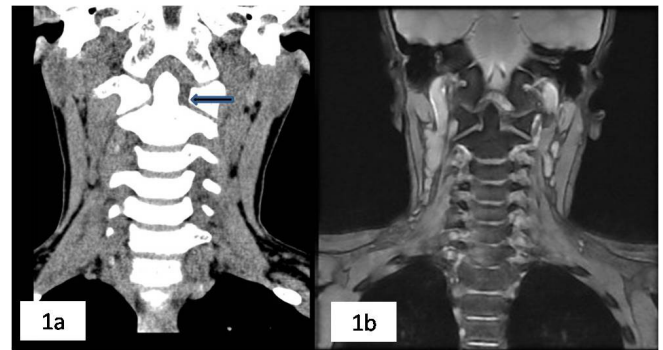

Fig.1(a): Cor reformatted CT, **(b):** Cor T2W MRI images reveal laxity of the left alar ligament with increased atlanto-axial distance (arrow) owing to lateral subluxation at the atlanto-axial joint.

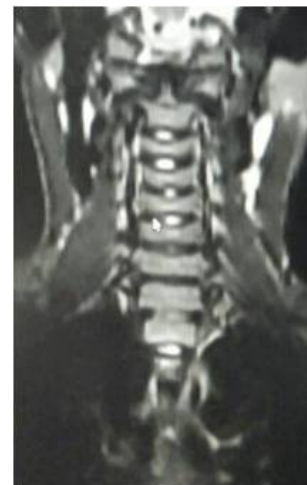


Fig.2: MRI image showing resolution of ligamental laxity with normal alignment of the atlanto-axial joint.

diagnosis is mainly based upon clinical suspicion, the radiological investigations can detect the degree of subluxation of C1 over C2 vertebra and laxity of the stabilizing ligaments of cervical spine early in the course of illness [6]. In our case a cervical CT was done initially followed by a confirmatory MRI. Our case had increased atlanto-odontoid distance (4.4 mm) towards the left and laxity of left alar ligament which collaborates with C1-C2 subluxation.

Due to rarity of the disease and wide spectrum of clinical manifestations there are no formulated treatment protocols for Grisel's

syndrome. The most accepted staging system and treatment modalities for Grisel's syndrome was proposed by Fielding *et al.* as depicted in following **Table 1** [7].

Most common are type 1 and 2 subluxations without neurological symptoms. Spinal cord compression and severe neurological sequelae are associated with types 3 and 4. Generally type 1 and 2 subluxations are treated conservatively (i.e. bed rest, antibiotics, muscle relaxants and soft immobilization with cervical collar or traction). Irreversible neurological damage may occur if treatment is not instituted early [4]. Type 3 and 4 subluxations are unstable, hence they may require active orthopedic interventions like halo immobilization, C1-C2 fusion and arthodesis.

Our patient had Fielding Type 1 atlanto-axial subluxation with no neurological symptoms and was therefore managed conservatively with bed rest, cervical collar and muscle relaxants. She showed gradual but full recovery over 4 weeks and showed complete resolution of the imaging findings.

Conclusion

Grisel's syndrome is a rare clinical entity that may be seen in a variety of clinical settings. Clinicians should be familiar with its demographic profile, wide spectrum of clinical presentation and treatment. Children are especially prone due to pre-existing cervical ligament laxity and hypermobility of C1 on C2. Any delay in diagnosis and instituting timely treatment may result in irreversible neurological deficit and fatal outcome. With a high index of suspicion and instituting early management, full functional recovery can be achieved in these cases.

Contributors: PH: manuscript writing, patient management; KNS, AD: manuscript editing, patient management. RSN: critical inputs into the manuscript, images. PH will act as guarantor. All authors approved the final version of the manuscript.

Funding: None; *Competing interests:* None stated.

Table 1: Staging system of Grisel syndrome.

Staging	Description	Therapy
Type I	No subluxation. Fixed rotation of atlas and axis. Dislocation less than 3 mm	Soft neck brace.
Type II	Unilateral atlanto-axial joint subluxation. The contralateral joint is pivotal. Ventral dislocation between 3 and 5 mm.	Conservative treatment.
Type III	Ventral subluxation of C1 in both joints. Ventral dislocation more than 5 mm.	Closed reposition, halo extension
Type IV	Dorsal subluxation of C1. Combination with fractured Dens axis or congenital dens aplasia is possible.	Operative treatment, fusion of C1-C2.

References

1. Beyazal MS, Demirok D, Çapkin E, Usul H, Tosun M, Sarı A. Grisel's Syndrome: a case report. *Turkish Journal of Rheumatology*. 2011;26:243-247.
2. Bocciolini C, Dall'Olio D, Cunsolo E, Cavazzuti PP, Laudadio P. Grisel's syndrome: a rare complication following adenoidectomy. *Acta Otorhinolaryngologica Italica*. 2005;25:245-249.
3. Ortega-Evangelio G, Alcon JJ, Alvarez-Pitti J, Sebastia V, Juncos M, Lurbe E. Eponym: Grisel syndrome. *European Journal of Pediatrics*. 2011;170:965-968.
4. Harma A, Firat Y. Grisel syndrome: non-traumatic atlantoaxial rotator subluxation. *Journal of Craniofacial Surgery*. 2008;19:1119-1121.
5. Wilson BC, Jarris BL, Haydon RC III. Non-traumatic subluxation of the atlantoaxial joint: Grisel's syndrome. *Ann Otol Rhinol Laryngol*. 1987;96:705-708.
6. Dağtekin A, Kara E, Vayısoğlu Y. The importance of early diagnosis and appropriate treatment in Grisel's syndrome: report of two cases. *Turkish Neurosurgery*. 2011;21:680-684.
7. Fielding JW, Hawkins RJ, Hensinger RN, Francis WR. Atlanto-axial rotary deformities. *Orthopedic Clinics of North America*. 1978;9:955-967.