doi:10.17659/01.2025.0020

Journal of Case Reports 2025;15(4):73-76

Incidental Follicular Cholecystitis: A Rare Occurrence

Shivangi Mittal, Zeeba S. Jairajpuri, Monal Trisal, Ritu Ojha, Sujata Jetley, Shaan Khetrapal

Department of Pathology, Hamdard Institute of Medical Sciences and Research, Jamia Hamdard University, New Delhi, India.

Corresponding Author:
Dr Shaan Khetrapal
Email: shaankhetrapal@gmail.com

This is an Open Access article distributed under the terms of the Creative Commons Attribution License (creativecommons.org/licenses/by/3.0).

Received : March 28, 2025
Accepted : May 26, 2025
Published : October 5, 2025

Abstract

Background: Follicular cholecystitis is a rare variant of chronic cholecystitis which is often missed or misdiagnosed on imaging. It is defined as at least three lymphoid follicles per cm of gallbladder (GB) tissue with an inflammatory infiltrate composed almost exclusively of scattered, well-formed lymphoid follicles. *Case Report*: The present case was preoperatively diagnosed as chronic cholecystitis, as the patient presented with similar symptoms. Ultrasonography indicated a thickened gallbladder wall with a single stone. Gross examination revealed a denuded mucosal lining and thickening of the wall. Microscopic analysis showed numerous lymphoid follicles, some with germinal center formation, leading to a histopathological diagnosis of follicular cholecystitis. *Conclusion*: Follicular cholecystitis (FC) is a rare benign gallbladder condition that can be challenging to diagnose, often resembling lymphoma. Accurate diagnosis requires careful histopathological examination and immunohistochemical (IHC) analysis.

Keywords: Cholecystitis, Gallbladder, Histopathology, Lymphoma, Ultrasonography.

Introduction

Gallbladder is one of the most frequently examined specimens in the surgical pathology laboratory for a variety of gallbladder diseases which include cholelithiasis, gallbladder carcinoma, gallbladder polyp and acalculous cholecystitis. Among these majority of cholecystectomies are done for symptomatic cholelithiasis which is a cause for chronic irritation from these gallstones invoking an inflammatory response in the gallbladder wall and hence the most frequent pathologic diagnosis being chronic cholecystitis. Follicular cholecystitis (FC) is identified as a rare unique variant of chronic cholecystitis that may be missed or misdiagnosed on radiological or clinical evaluation. FC is seen in less than 2% of all the cholecystectomy specimens [1,2]. This case report aims to highlight the rarity of this entity and discusses its diagnostic pitfalls and clinical associations. Documenting its clinical course and pathological features will aid in better recognition and management of this uncommon entity.

Case Report

We report here the case of a 35-year-old female, preoperatively diagnosed with gallstone disease. The patient presented to the hospital with intermittent abdominal pain and postprandial nausea. Laboratory investigations revealed bilirubin and liver enzymes within normal limits. Ultrasonography of the abdomen revealed distended gall bladder with a calculus (12×7 mm) and thickening of the wall (4 mm). CBD was normal with Grade 1 fatty liver. A diagnosis of symptomatic cholelithiasis was made and she underwent laparoscopic cholecystectomy. The intraoperative findings showed distended thick-walled GB containing solitary calculus impacted at the neck, omental adhesions with fundus and body. The postoperative course was uneventful and the patient was discharged three days after surgery.

Specimen was sent for histopathology where gross examination showed the wall to be externally congested with a completely denuded

© 2025 Journal of Case Reports

mucosa. The wall was thickened varied in thickness from 0.8-0.9 cm **[Fig.1]**. One lymph node was also identified near the cystic duct end. On microscopy, a partially denuded mucosal lining with focal areas of preservation was observed. The wall showed many lymphoid aggregates with few of them showing germinal center formation along with changes of chronic cholecystitis such as smooth muscle hypertrophy, fibrosis, and transmural chronic inflammatory infiltrate. Hence, a histopathological diagnosis of follicular cholecystitis was made **[Fig.2,3,4]**. Immunohistochemistry showed these follicles staining positive for CD20 **[Fig.5,6]**.

Fig.1: *Gross images showing a thickened gall bladder wall with a denuded mucosa.*

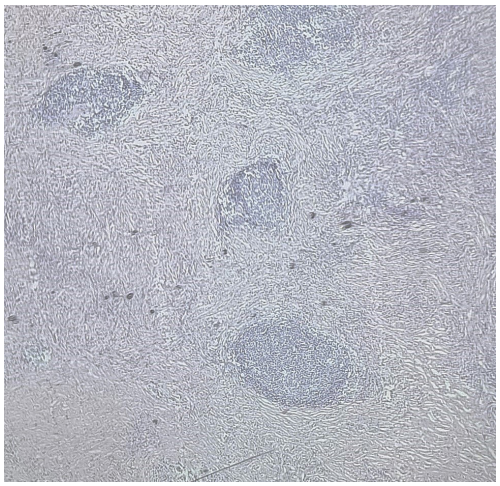

Fig.2: *Lymphoid follicles in the wall of the gall bladder (H&E, 4×).*

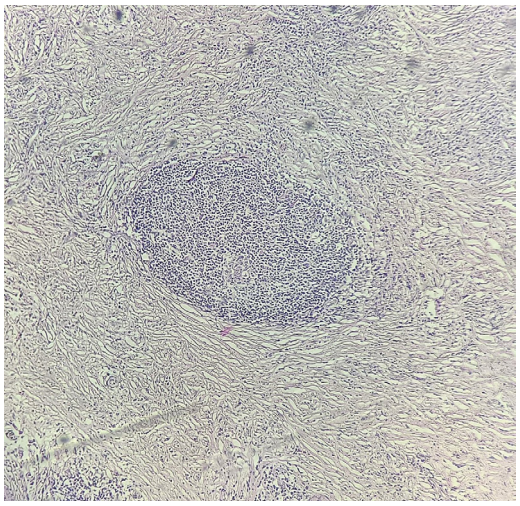

Fig.3: *Lymphoid follicles in the wall of the gall bladder (H&E, 10×).*

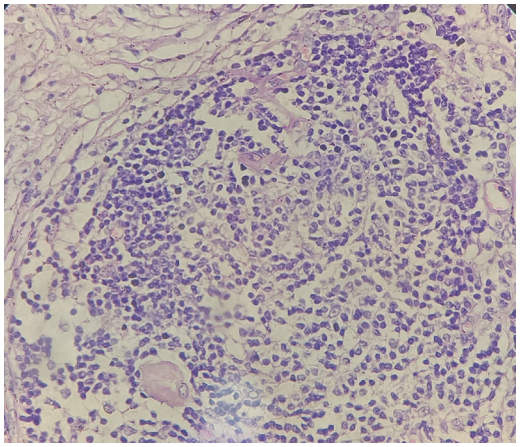

Fig.4: *Thickened wall, fibrosis, dense chronic inflammation suggestive of chronic cholecystitis (H&E).*

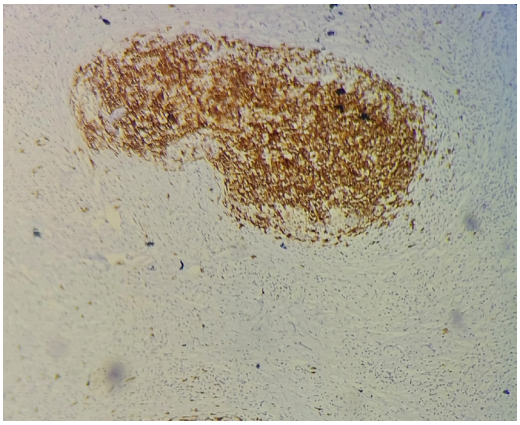

Fig.5: *Immunohistochemistry showing CD20 staining in the lymphoid follicle (10×).*

© 2025 Journal of Case Reports

Discussion

FC is a benign lesion characterized histologically by hyperplastic lymphoid follicles with germinal centers that can be found anywhere in the wall of the gall bladder, most commonly seen in the mucosal layer. In India, only a few reports exist, with larger studies showing an incidence of 0.25%-6% of cholecystectomies [3-7].

The etiopathogenesis of FC is unknown. Historically, it has been reported to be associated with gram-negative bacteria such as *S. typhi, E. coli* [2]. Other possible theories include an autoimmune-mediated disorder in other areas of the gastrointestinal tract. Saka B *et al*. in 2020 proposed that a disrupted immune response could be a potential underlying cause [1]. A study by Salari B *et al*. 2019 reported it to be associated with extrahepatic biliary obstruction occurring beyond the gallbladder, including conditions like primary sclerosing cholangitis, choledocholithiasis, and distal biliary strictures [2]. A case report by Piening *et al*. in 2022 was the first to document FC with hepatic periductal fibrosis [8]. However, Saka B *et al*. in 2020 found that FC does not seem to be connected with autoimmunity, lymphoma, or obstructive pathologies, which is at odds with the conclusions drawn by the other studies [1]. Thus, the clinical significance of FC remains unclear, and a comprehensive retrospective clinical assessment is needed to clarify its precise relationship with the above-mentioned conditions.

Although cases of chronic cholecystitis are more frequently seen in middle-aged females, a few large cohort studies have reported FC to be more often seen in older patients with the median age being 67 years in a study by Salari B *et al*. in 2019 and 68 years by Saka B *et al*. in 2020 [1,2]. Our patient was 35 years old at the time of FC diagnosis, which is significantly younger than the typical FC patient. Ultrasound findings are often similar to that of chronic cholecystitis with most common being the thickening of the gall bladder wall and calculi in the lumen. However, findings of adenomyosis, possible gallbladder polyps and hypoechoic intramural nodules have also been reported which mimic xanthogranulomatous cholecystitis and malignancy [8,9]. Thus, creating a diagnostic dilemma for the surgeons.

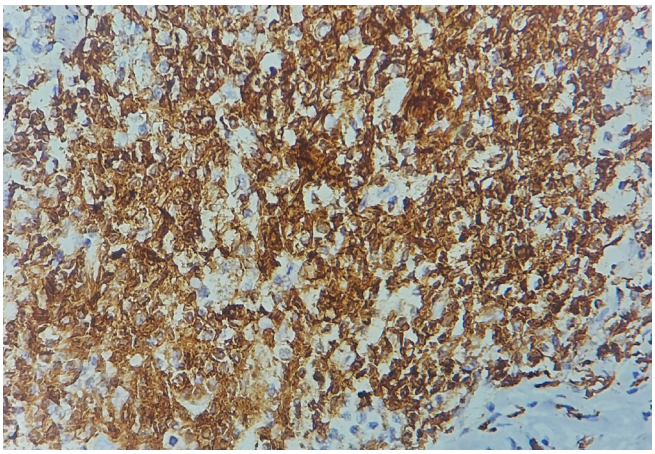

Fig.6: *Immunohistochemistry showing CD20 staining in the lymphoid follicle (40×).*

Although this condition is rare and benign, it is crucial to differentiate it from gallbladder lymphomas, such as MALT lymphoma and follicular lymphoma, because their histological features can be quite similar. Distinguishing between reactive lymphoid hyperplasia and neoplastic lymphoid proliferation follows similar principles used for lymph nodes. Atypical features include nonpolarized germinal centers, attenuated mantle zones lacking tingible body macrophages. In more complex cases, immunohistochemistry (IHC) can be employed to aid in the differentiation (CD19, BCl2, CD21, Ki67, kappa/lambda).

Conclusion

Follicular cholecystitis is a rare benign entity among gall bladder diseases that can sometimes present a diagnostic challenge for both surgeons and pathologists. Reporting this case was vital to improve recognition, guide management, and build evidence for future therapeutic decisions.

© 2025 Journal of Case Reports

Contributors: SM, RO: manuscript writing and literature search; MT: manuscript editing; SK, ZSJ: concept and design; SJ: critical inputs into the manuscript. SK will act as a study guarantor. All authors approved the final version of this manuscript and are responsible for all aspects of this study.
Funding: None; *Competing interests*: None stated.

References

1. Saka B, Memis B, Seven IE, Pehlivanoglu B, Balci S, Bagci P, *et al*. Follicular cholecystitis: reappraisal of incidence, definition, and clinicopathologic associations in an analysis of 2550 cholecystectomies. International Journal of Surgical Pathology. 2020;28(8):826-834.
2. Salari B, Rezaee N, Toland A, Chatterjee D. Follicular cholecystitis: clinicopathologic associations. Human Pathology. 2019;88:1-6.
3. Bhosale NM, Patil MA, Pol VJ, Pol JN. Follicular cholecystitis with cholelithiasis a diagnostic pitfall. IP Journal of Diagnostic Pathology and Oncology. 2021;6(4):316-318.
4. Rana S, Jairajpuri ZS, Khan S, Hassan MJ, Jetley S. Gall bladder lymphoid hyperplasia: masquerading as lymphoma. Journal of Cancer Research and Therapeutics. 2014;10(3):749-751.
5. Singh M, Vishwakarma I, Kumar J, Omhare A, Mishra V, Verma YN. Follicular cholecystitis with cholelithiasis: a rare case report. Int J Life Sci Scienti Res. 2017;3(5):1408-1410.
6. Vats AD, Gupta V, Mehendiratta M, Anand N. Chronic cholecystitis with follicular lymphoid hyperplasia: nomenclature and diagnostic dilemmas. Int J Res Med Sci. 2019;7(3):770-775.
7. Mohan H, Punia RP, Dhawan SB, Ahal S, Sekhon MS. Morphological spectrum of gallstone disease in 1100 cholecystectomies in North India. Indian J Surg. 2005;67(3):141-142.
8. Piening N, Zussman R, Markewycz H, Piening C, Rossi T. Incidental follicular cholecystitis with periductal fibrosis on liver biopsy: rare findings. International Journal of Surgery Case Reports. 2022;98:107571.
9. Aineseder M, Grove RL, Mullenl EG, Spina JC. Follicular cholecystitis mimicking xanthogranulomatous cholecystitis and malignancy: a case report. Indian Journal of Radiology and Imaging. 2021;31(03): 697-700.

© 2025 Journal of Case Reports